

Gain an objective look at localized retinal dysfunction.

DIOPSYS® mfERG

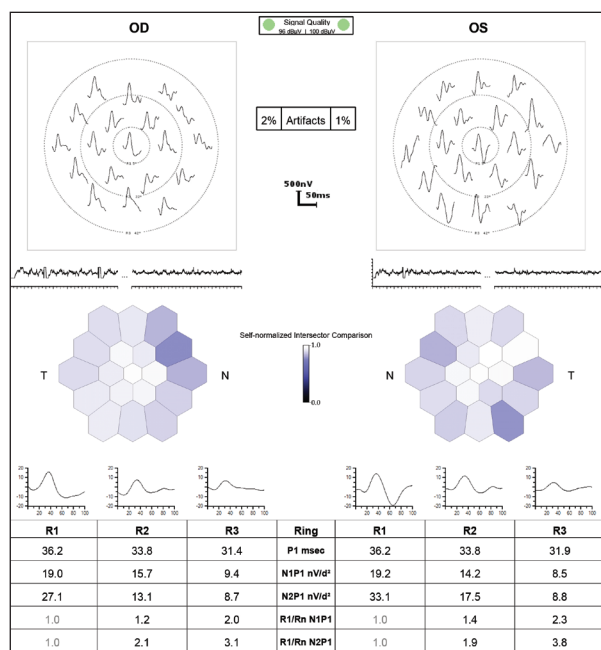
MULTIFOCAL ELECTRORETINOGRAPHY

• objective • functional • accessible

Diopsys® mfERG vision tests provide objective information about localized retinal function to help recognize the first signs of drug-induced retinopathy.¹⁻² In some cases, retinal dysfunction may occur before structural abnormalities, requiring a robust functional testing method to detect retinal toxicity early.²⁻⁴

- Monitor retinal function loss and recovery with objective, quantitative metrics²⁻³
- Co-manage patients more efficiently for more timely changes to treatment

Healthy Eyes

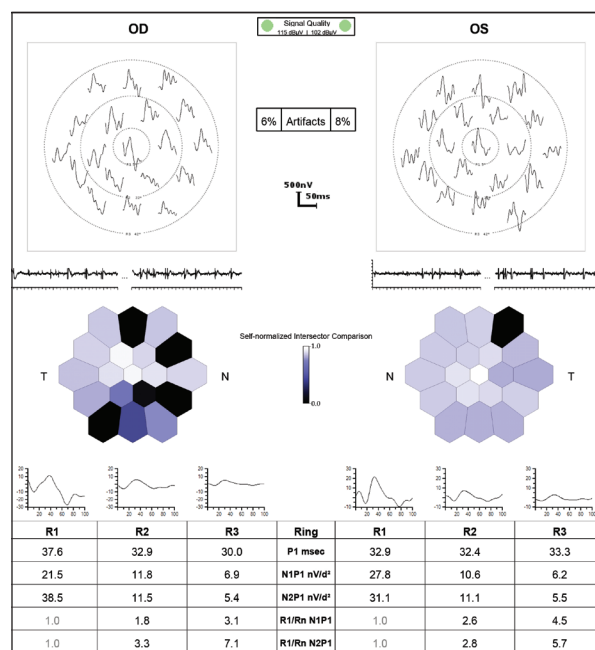


- Clearly defined waveforms.
- Mostly white to lighter blue sectors.
- Ring ratio data within expected ranges.*

Conclusion: Suggests good retinal function.

In this case, the eye care provider scheduled a follow-up to retest in one year.

Plaque Toxicity



- Atypical waveforms.
- Darker blue to black sectors.
- Ring ratios outside expected ranges.*

Conclusion: Suggests poor retinal function.

In this case, the eye care provider notified prescribing physician with suggestion to stop medication immediately to prevent further damage, unless medically critical.

Detect developing toxicity early.²⁻⁴
Enhance co-management.



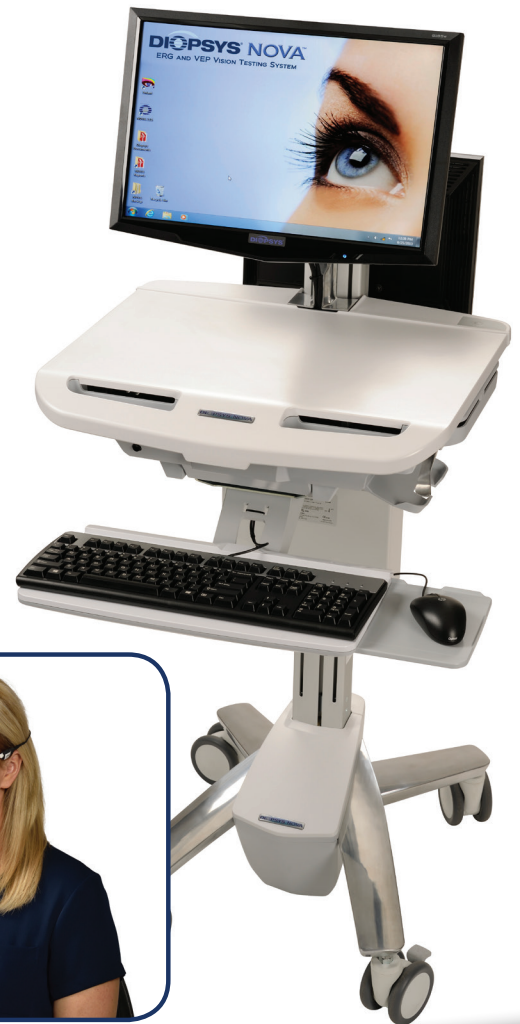DIOPSYS[®] mfERG
MULTIFOCAL ELECTRORETINOGRAPHY
• objective • functional • accessible

Most ocular side effects of drug-induced toxicity are reversible after cessation of therapy **if detected early**.² However, taking a patient off certain medications can be life altering.

Multifocal ERG test results can help eye care providers¹⁻⁵

- Confirm dysfunction when visual fields are abnormal
- Support continuation of medication when test results show healthy retinal function

The American Academy of Ophthalmology (AAO) recommends the use of multifocal electroretinography for chloroquine (CQ) and hydroxychloroquine (HCQ) retinopathy screening.⁴



To learn more, visit Diopsys.com/multifocal
or call 1-973-244-0622.

1. Hood, DC, et al. ISCEV Standard for clinical multifocal electroretinography (2011 edition). Doc Ophthalmol 124:1-13. 2. Dettoraki M, Moschos MM. The Role of Multifocal Electroretinography in the Assessment of Drug-Induced Retinopathy: A Review of the Literature. Ophthalmic Res 2016;56:169-177. 3. Talamini CL, et al. Abnormal multifocal ERG findings in patients with normal-appearing retinal anatomy. Doc Ophthalmol 2011;123(3):187-192. 4. Marmor, M, et al. Recommendations on Screening for Chloroquine and Hydroxychloroquine Retinopathy (2016 Revision). Ophthalmology 2016;123:6:1386-1394. 5. Hansen, MS, et al. Ophthalmic Pearls: Hydroxychloroquine-Induced Retinal Toxicity. EyeNet June 2011:33-35.